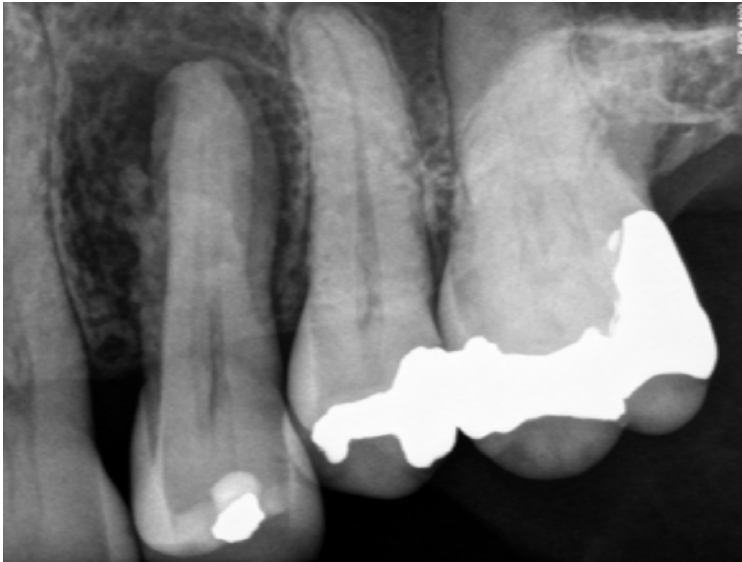
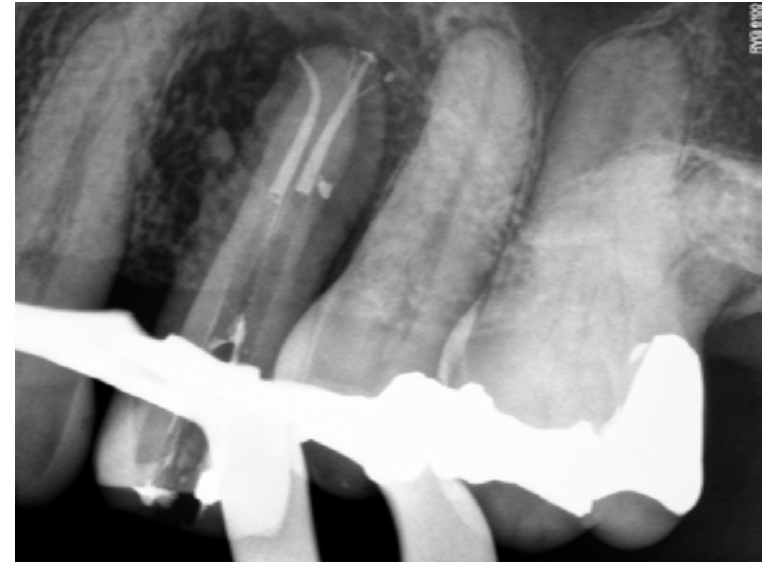

# PROTAPER•NEXT™ Clinical Case



Maxillary left first premolar. Nonvital pulp had resulted in radiographic lesion of endodontic origin.



Obturation downpack image demonstrating 2 canals and 5 visible portals of exit sealed. PROTAPER NEXT provides predictable deep shaping preparations for confident and consistent 3D obturation regardless of obturation technique.